

"Cat Got Your Tongue?"

Low Value Care in a Diagnosis of Cat Scratch Disease

Shree Patel, DO

Our Lady of the Lake Pediatric Residency Program



Disclosure

Dr. Patel has no relevant financial relationships with commercial interest to disclose.

Her presentation will not include discussion of commercial products and or services.

Dr. Bolton is the physician planner. He has no relevant financial relationships with commercial interest to disclose.

The OLOL CME Committee has no relevant financial relationships with commercial interest to disclose.

Thank you!



Purpose

- The purpose of this case presentation is to review the diagnosis and management of cat scratch disease (CSD) and to highlight the low value of care provided to a patient with a typical presentation of CSD.



Goals and Objectives

- Case Presentation
- Lymphadenitis diagnostic approach
- Background on CSD
- Discussion of low value care



HPI

- 7 year old patient presented to PCP office with a chief complaint of left-sided neck swelling and fevers of 1 week.
 - Quality of pain was throbbing.
 - Good PO intake and UOP.
 - No trouble swallowing or SOB.
 - Strep and mononucleosis were negative, bartonella titers were sent, and patient was started on clindamycin.
- **Antibiotic: \$200**
- **Labs: \$200**
- **Cumulative Cost: \$400**



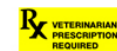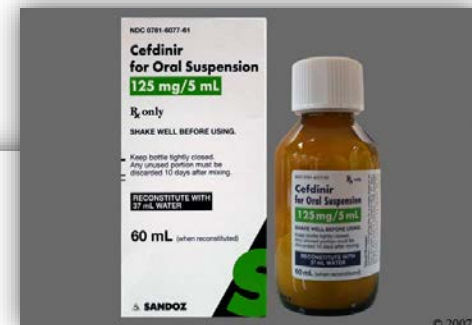HPI

- 5 days later
 - Labs returned with elevated *Bartonella henselae* IgG $\geq 1:1024$ and normal *Bartonella henselae* IgM
 - Pediatrician was unaware of the lab results.



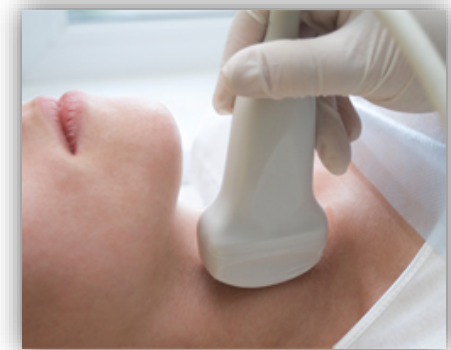HPI

- Despite elevated IgG, clindamycin was continued.
- Due to persistent swelling after 11 days of clindamycin, patient was switched to cefdinir and sulfamethoxazole-trimethoprim.
- **Antibiotics: \$90**
- **Cumulative Cost: \$490**



HPI

- ~17 days after initial evaluation by PCP
 - Neck ultrasound done to due persistent lymphadenopathy
 - Hypodense mass in the left submandibular gland.
- Patient admitted for IV antibiotics.
- **Hospital Stay \$7,500**
- **Neck US \$246**
- **Cumulative Cost: \$8,236**



PHYSICAL EXAM

- **Vitals: T 98.4, BP 112/59, HR 125, RR 30, O2 sat 100% on room air**
- General: Alert and oriented, Well nourished, No acute distress.
- Eye: Within normal limits, Pupils are equal, round and reactive to light, Extraocular movements are intact, Normal conjunctiva.
- HEENT: Normocephalic, Pupils are equal, round and reactive to light, Normal hearing, Oral mucosa is moist. Ears, Nose, Mouth, Throat WNL.
- Neck: **Firm, non-erythematous 5 cm left submandibular swelling. Tender to palpation. Limited active ROM of jaw due to pain.**
- Respiratory: Lungs are clear to auscultation, Respirations are non-labored, Breath sounds are equal.
- Cardiovascular: Tachycardic, Regular rhythm, No murmur, No gallop, No edema.
- Gastrointestinal: Soft, Non-tender, Non-distended, Normal bowel sounds.
- Genitourinary: Exam deferred.
- Musculoskeletal: No tenderness, No deformity.
- Integumentary: Warm, Dry, Pink.
- Neurologic: Alert, Oriented.
- Psychiatric: Cooperative.



WORKUP

- CBC: WBC 8.7, H/H 13.1/37.5, platelets 391
- Differential: 51% neutrophils, 39% lymphocytes, 7% monocytes, 2% eosinophils, 1% basophils
- ESR 24 mm/h
- Blood culture drawn
- Imaging: Neck ultrasound and CT neck with IV contrast



IMAGING

- US Head/Face/Neck/Soft Tissue:
 - Left submandibular gland region with heterogeneous mass measuring 2.3 x 2.2 x 1.4 cm
- CT Neck w/IV contrast:
 - Left submandibular gland diffusely enlarged compared to right. There is a small hypodense collection measuring 1.6 x 1.5 x 1.1 cm. There are multiple lymph nodes in the left neck which appear reactive. The underlying mandible is intact.
- **Second Neck US \$246**
- **CT \$529**
- **Cumulative Cost: \$9,011**



COURSE OF EVENTS

- She was made NPO and placed on maintenance IVF, and started on IV clindamycin 10mg/kg q8h.
- ENT consult: No indication for immediate drainage. Recommend continuing IV antibiotics, keep NPO, on mIVF. Plan to reassess.
- **Hospital Day (HD) #2-4:** monitored on IV clindamycin, no improvement.
- **IV antibiotics: \$325**
- **Cumulative Cost: \$9,336**



COURSE OF EVENTS

- **HD#5:** US guided needle biopsy and FNA performed by ENT. Fluid sent off for stain, culture, AFB.
- **HD #6:** Attending hospitalist discussed with ENT to wait for Bartonella PCR to return prior to further surgery as ENT planned on removal of mass. ID consulted as mass still present and recommended to perform PPD.
- **FNA \$274**
- **Labs ~\$200**
- **Cumulative Cost: \$9,810**



HPI

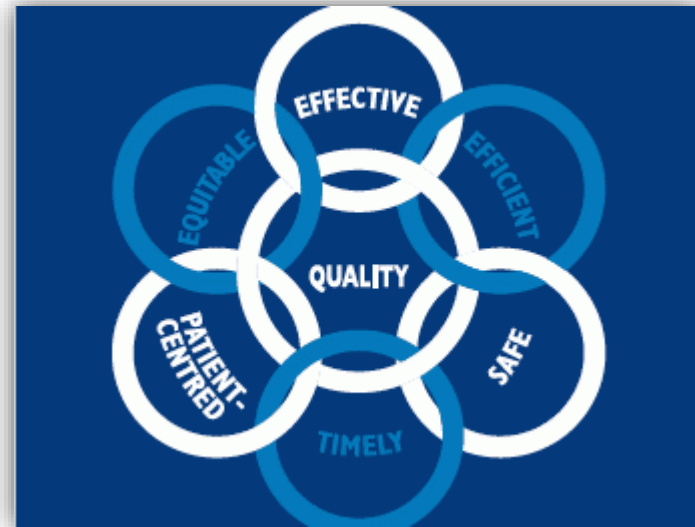- Discharged home while awaiting biopsy results.
- Six days after being discharged from the hospital, Bartonella PCR from the FNA resulted positive.
- Upon review of initial labs sent by PCP, it was noted for the first time the Bartonella titers were positive.



CUMULATIVE COST

\$9,810

How could this have been prevented?



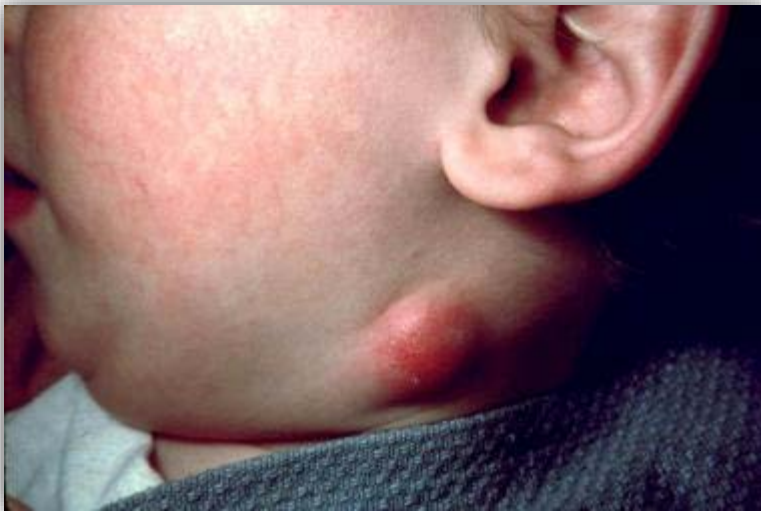LYMPHADENITIS DIAGNOSTIC APPROACH

- Thorough H&P dictates management route
- Management ranges from observation and reassurance to comprehensive diagnostic testing and aggressive medical and surgical therapy
- In difficult cases, consultation with specialist in pediatric infectious disease

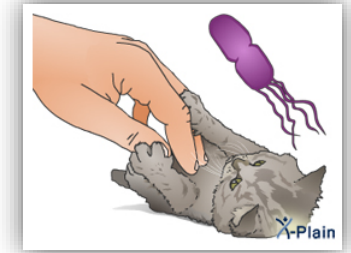
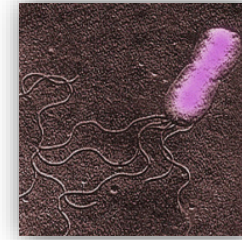


LYMPHADENITIS HISTORY

- Duration
 - Subacute/chronic - weeks
- Laterality
- Associated symptoms (fever, weight loss, fatigue, malaise, conjunctivitis, pharyngitis, dental problems, cough, arthralgia, skin lesions, trauma)
- Immunization status
- Exposures
- Ill contacts
 - Viral infections, CMV, EBV, GAS, TB
- Ingestion of unpasteurized milk or undercooked meats
 - Brucellosis
 - Mycobacterium bovis
 - Toxoplasmosis
- Animal exposure
 - Cat scratch disease
 - Toxoplasmosis (cats)
 - Brucellosis (goats)
 - Tularemia (rabbits)
 - Bubonic plague (prairie dogs)
- Flea or tick bites
 - Bubonic plague
 - Tularemia
- Medications
 - Phenytoin
 - Carbamazepine
- Geographic location or travel



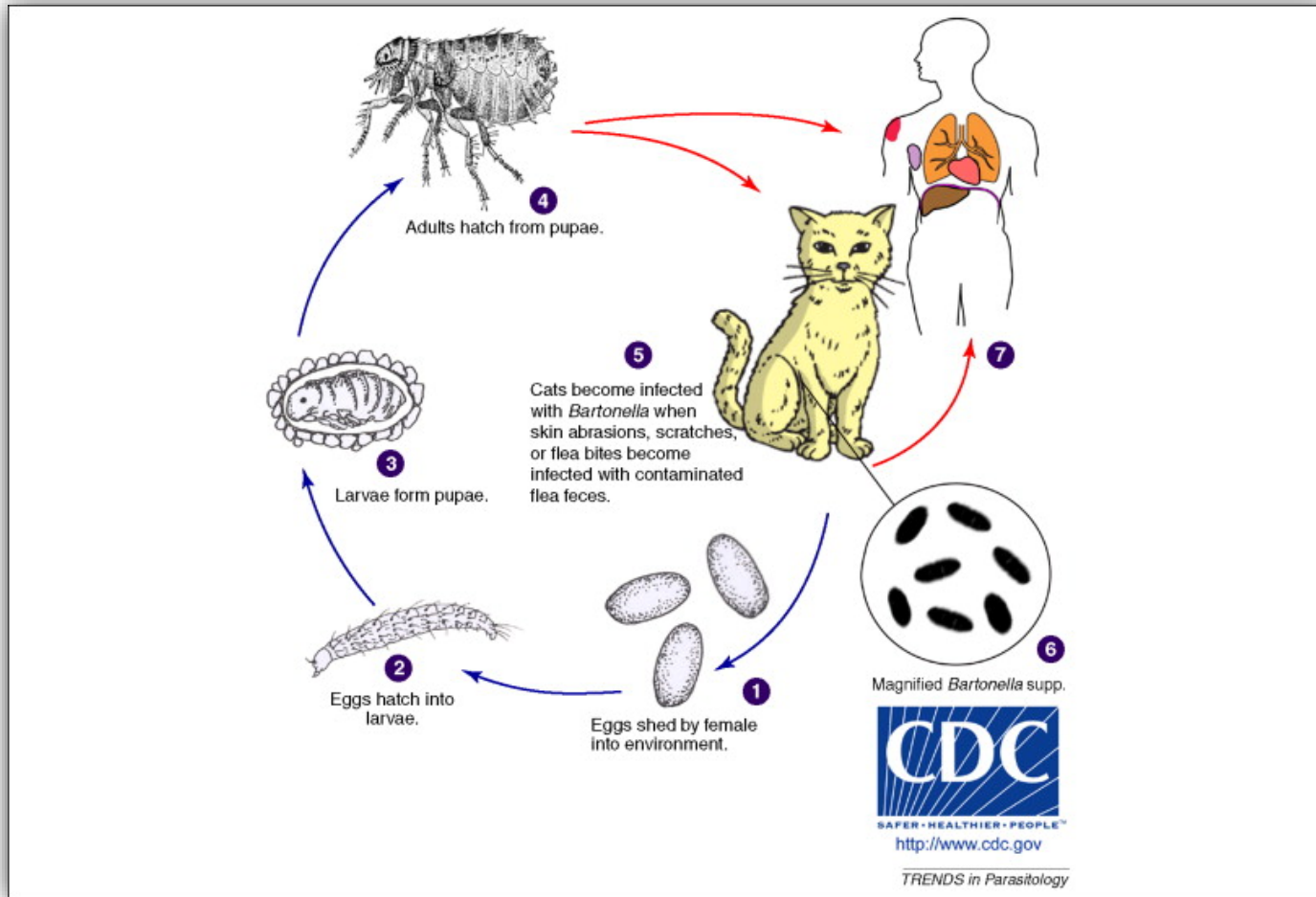
CSD BACKGROUND



- Cat scratch disease is a self-limited illness caused by *Bartonella henselae* that presents approximately 3 to 10 days after inoculation via a cat scratch or bite or flea bite.
- Typically begins with primary inoculation lesion, which may be nodular or pustular that can persist for one to three weeks.
- Those under age 10 are most commonly affected, and infection is more prevalent in the fall and early winter.
- Axillary, epitrochlear, cervical, supraclavicular, or submandibular lymphadenopathy is the hallmark presentation of CSD and persists for weeks to months. Nodes are usually tender and often with overlying erythema.
- Rarely, bloodborne disseminated infection can cause ocular manifestations (Parinaud's oculoglandular syndrome, neuroretinitis), visceral organ involvement, bacillary angiomatosis, or meningo-encephalitis.



B. henselae transmission



DIAGNOSIS OF CSD

- Diagnosis may be suspected from typical clinical findings, but laboratory evaluation is necessary to confirm the clinical presentation.
- 3 of the following criteria must be present to diagnose Cat Scratch Disease (CSD):
 - cat or flea contact regardless of the presence of an inoculation site lesion
 - negative serology for other causes of adenopathy; sterile pus aspirated from a node; positive *Bartonella* PCR assay; and/or liver or spleen lesions seen on CT scan
 - positive serology for *B. henselae*: enzyme immunoassay [EIA] or indirect fluorescence assay [IFA]
 - biopsy showing granulomatous inflammation consistent with CSD or a positive Warthin-Starry silver stain
- Isolation of *B. henselae* by culture provides a definitive diagnosis, but it is difficult to isolate from tissue specimens
- Positive serologic test is generally adequate to diagnose patients that have typical clinical manifestations of CSD



WARTHIN-STARRY SILVER STAIN

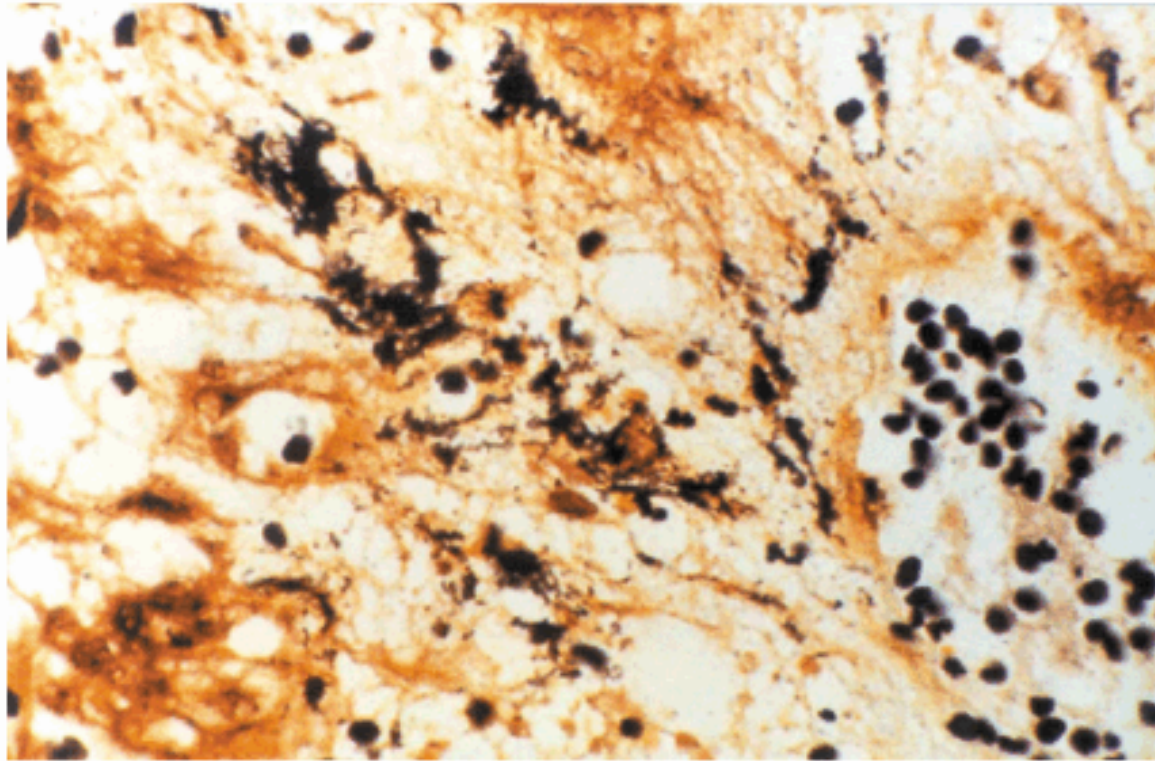


Fig. 1 - Silver-impregnation technique (Warthin-Starry) in a lymph node biopsy showing a conglomerate of black colored *Barthoneilla* bacillus (40X)

www.pathologyoutlines.com



DIAGNOSIS

- Titers between 1:64 and 1:256 represent possible Bartonella infection; repeat testing in 10 to 14 days is recommended
- IgG >1:256 strongly suggests active or very recent infection. Because the production of IgM is usually brief, the serologic diagnosis of acute infection can be elusive.



CSD MANAGEMENT

- Supportive
- Azithromycin and rifampin, possibly trimethoprim-sulfamethoxazole
- Do not incise and drain
 - Risk of persistent sinus tract
- Node biopsy may be required in atypical cases



DISCUSSION OF LOW VALUE CARE

- Estimated cost of this patient's care is greater than \$10,000.
- Factors that could have prevented unnecessary workup
 - Step-by-step approach of diagnosing lymphadenopathy
 - Better laboratory follow-up
 - Better communication amongst the pediatrician and hospital providers
- Outpatient monitoring and, if needed, outpatient referral to ENT or pediatric infectious disease would have been more equitable.



DISCUSSION OF LOW VALUE CARE

- Outpatient evaluation would have been a safe avenue since this patient was well-appearing, afebrile, with stable vital signs and positive IgG for CSD.
- The patient was exposed to unnecessary radiation, underwent general anesthesia, experienced post-operative pain from the biopsy, and was put at risk for nosocomial infections.
- Throughout this patient's care, multiple providers were involved in her care, which may have further contributed to the missed diagnosis.
- Better communication amongst providers and a thorough evaluation of lymphadenopathy could have prevented all of the above.



REFERENCES

- Healy M. “Cervical lymphadenitis in children: Diagnostic approach and initial management.” UpToDate 2016.
- Spach D and Sheldon K. “Microbiology, epidemiology, clinical manifestations, and diagnosis of cat scratch disease.” UpToDate 2016.
- Healthcare Bluebook.
https://healthcarebluebook.com/page_Default.aspx
- <http://www.beckershospitalreview.com/lists/2011average-cost-per-inpatient-day-across-50-states.html>



The End!

